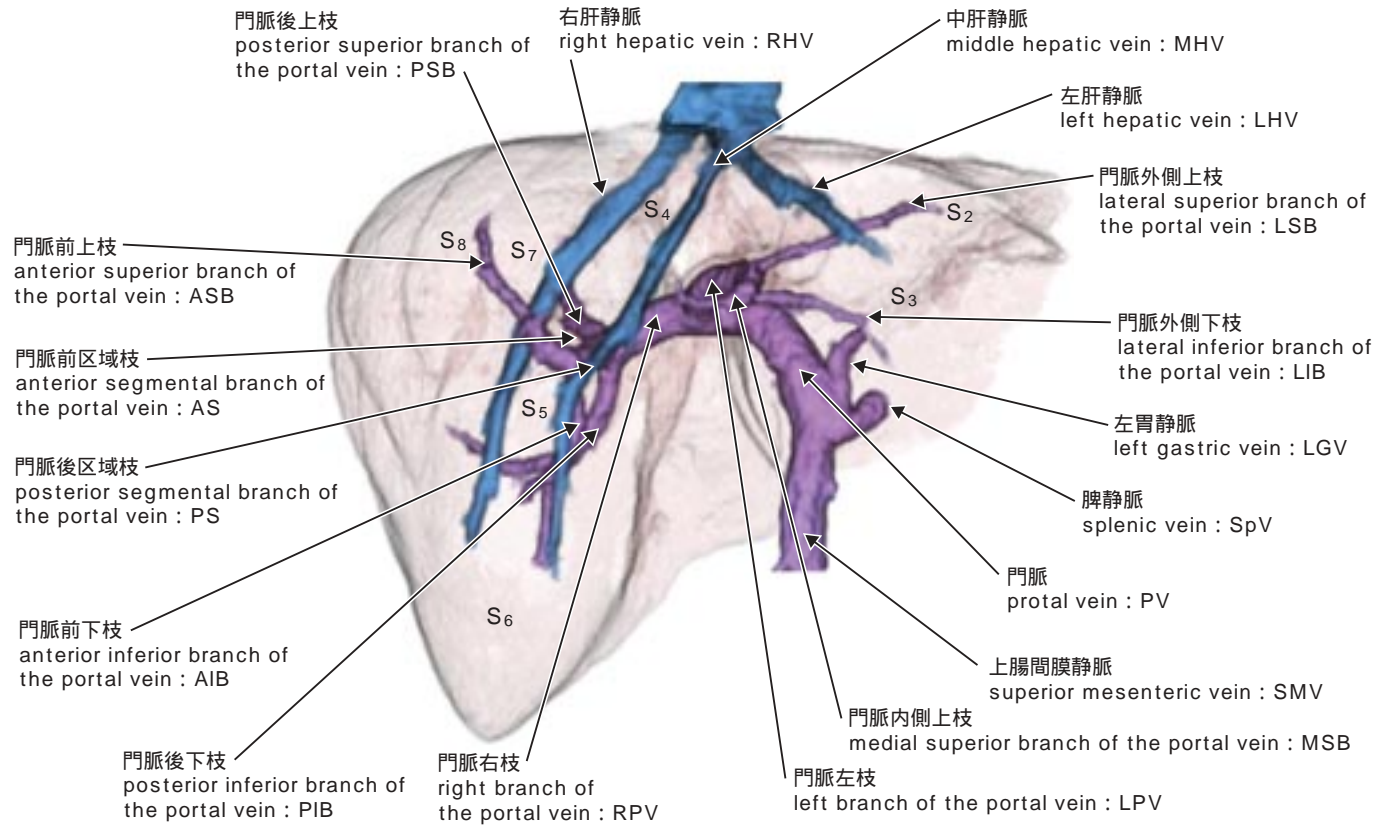
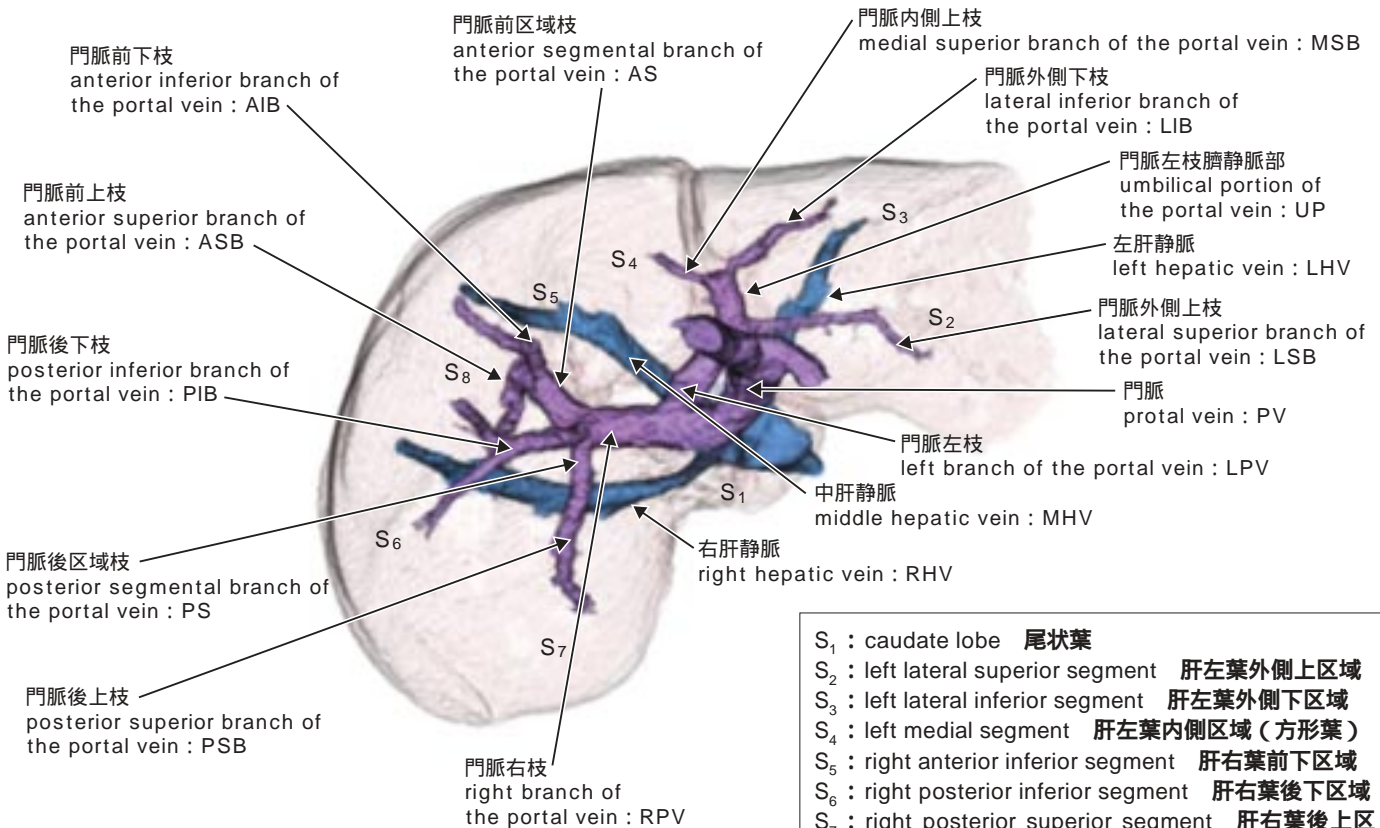


17-1-3 肝内門脈と肝静脈 (intrahepatic portal vein and hepatic vein)

17-1-3-1 肝内門脈と肝静脈〔前面図〕(3D-CT)

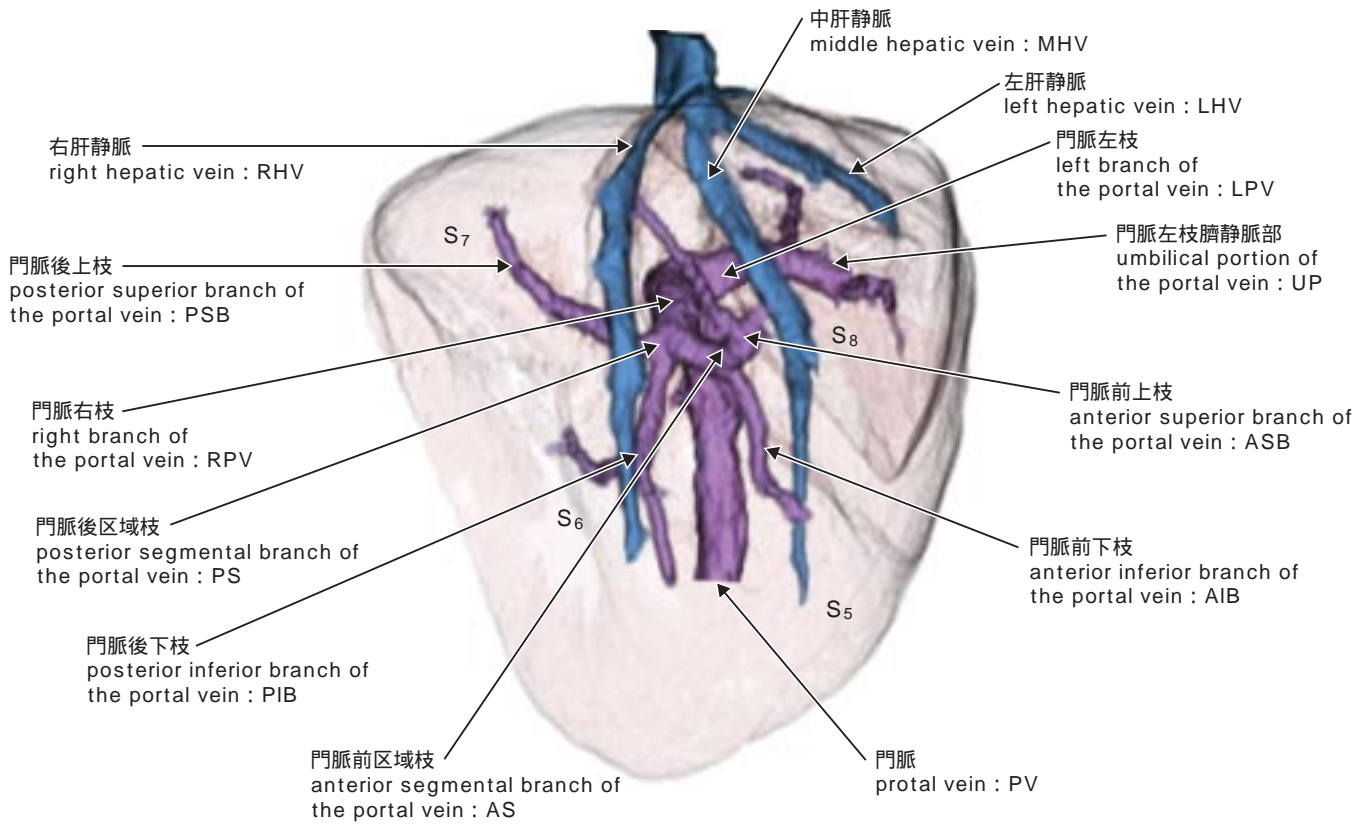


17-1-3-2 肝内門脈と肝静脈〔仰面図〕(3D-CT)

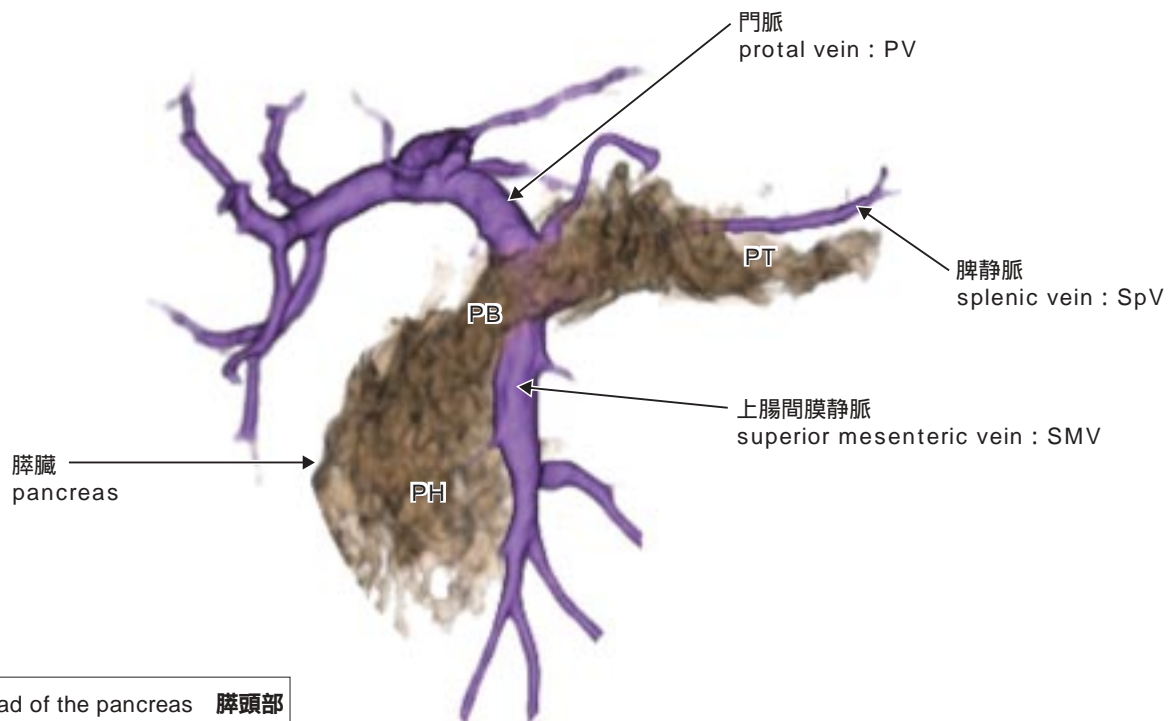


- S₁ : caudate lobe 尾状葉
- S₂ : left lateral superior segment 肝左葉外側上区域
- S₃ : left lateral inferior segment 肝左葉外側下区域
- S₄ : left medial segment 肝左葉内側区域 (方形葉)
- S₅ : right anterior inferior segment 肝右葉前下区域
- S₆ : right posterior inferior segment 肝右葉後下区域
- S₇ : right posterior superior segment 肝右葉後上区域

17-1-3-3 肝内門脈と肝静脈〔右側面図〕(3D-CT)



17-1-4 門脈と膵臓〔前面図〕(3D-CT)(portal vein and pancreas)



PH : head of the pancreas 膵頭部
 PB : body of the pancreas 膵体部
 PT : tail of the pancreas 膵尾部